

Glaucoma Diagnosis by Optic Cup to Disc Ratio Estimation

N. Ranjith, C. Saravanan, M. R. Bibin

Abstract— Glaucoma is a major global cause of blindness. An approach to automatically extract the main features in color fundus images is proposed in this paper. The optic cup-to-disc ratio (CDR) in retinal fundus images is one of the principle physiological characteristics in the diagnosis of glaucoma. The least square fitting algorithm aims to improve the accuracy of the boundary estimation. The technique used here is a core component of ARGALI (Automatic cup-to-disc Ratio measurement system for Glaucoma detection and AnaLysIs), a system for automated glaucoma risk assessment. The algorithm's effectiveness is demonstrated manually on segmented retina fundus images. By comparing the automatic cup height measurement to ground truth, we found that the method accurately detected neuro-retinal cup height. This work improves the efficiency of clinical interpretation of Glaucoma in fundus images of the eye. The tool utilized to accomplish the objective is MATLAB7.5

Keywords—Cup to Disc Ratio; Optic Nerve Head; Heidelberg Retinal Tomography; Convex hull; Region of Interest

I. INTRODUCTION

Glaucoma is a group of diseases that can damage the eye's optic nerve and result in vision loss and permanent blindness. Some of the alarming facts about glaucoma are: (1) Glaucoma is the leading cause of blindness, (2) There is no cure for glaucoma, with medication it is possible to halt further loss of vision and (3) Everyone is at risk from babies to senior citizens [1].

According to World Health Organization, glaucoma is the second leading cause of blindness; it is responsible for approximately 5.2 million cases of blindness (15% of the total burden of world blindness) [3] and will affect 60 million people by 2010 [4].

The ailment is physiologically described as the degeneration of optic nerve cells, and is characterized by changes in the optic nerve head and visual field. Although Glaucomatous damage is irreversible, early detection and subsequent medical intervention by ophthalmologists is effective in slowing the progression of the disease. Figure 1 shows the medical diagram of an eye representing the nomenclature used.

Manuscript Received on March 2015.

N. Ranjith, Final Year, Department of Electronics & Communication Engineering, Vel Tech Multi Tech Dr. Rangarajan Dr. Sakunthala Engineering College, Avadi-62, India.

C. Saravanan, Final Year, Department of Electronics & Communication Engineering, Vel Tech Multi Tech Dr. Rangarajan Dr. Sakunthala Engineering College, Avadi-62, India.

M. R. Bibin, Final Year, Department of Electronics & Communication Engineering, Vel Tech Multi Tech Dr. Rangarajan Dr. Sakunthala Engineering College, Avadi-62, India.

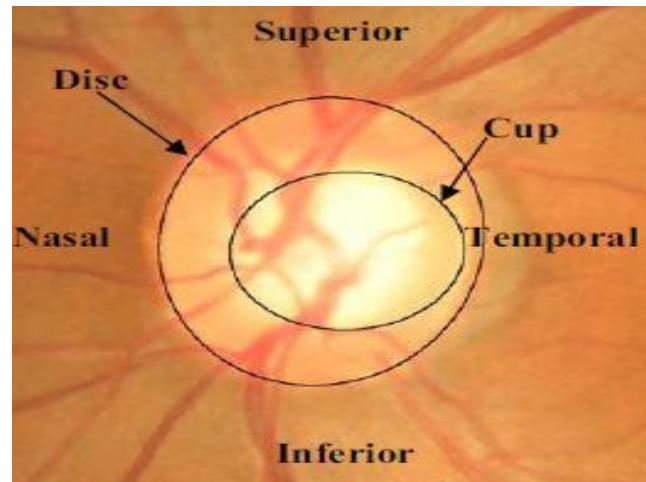
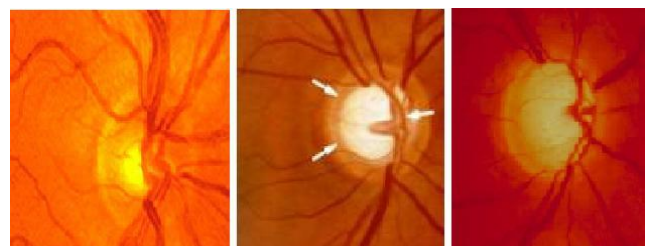


Figure 1: Medical diagram of an eye.

Figure 2 illustrates the optic nerve change along the three stages of glaucoma development. In the early stage of glaucoma, optic nerve damage starts without incurring any symptom, patients are not aware of the disease until advanced stage which is associated with total blindness. The damage caused is irreversible, but treatment can prevent progression of the disease if detected in the early stage. Thus, early detection of glaucoma is crucial.



(a) Normal optic (b) early glaucoma (c) Advanced glaucoma

Figure 2. Stages of progressive cupping in neuro-retinal optic disc and cup area for glaucoma patient. (a). Normal Stage, without any nerve damage, (b). Early Stage, nerve damage starts with no vision loss, normal or high intra-ocular pressure and (c). Advanced Stage, visual loss occurred.

Clinically, the diagnosis of Glaucoma can be done through measurement of CDR [2], defined as the ratio of the vertical height of the optic cup to the vertical height of the optic disc. An increment in the cupping of Optic Nerve Head (ONH) corresponds to increased ganglion cell death and hence CDR can be used to measure the probability of developing the disease. A CDR value that is greater than 0.65 indicates high glaucoma risk [5]. ONH assessment is manually

performed by a trained specialist or using specialized and expensive equipment such as the Heidelberg Retinal Tomography (HRT) system. Thus, there remains a lack of cost effective, sensitive and precise method to screen for glaucoma. Previously, many methods have been reported for optic disc detection [6, 7], but significantly fewer methods have been presented for optic cup detection, which is much more challenging due to the reduced visibility of the optic cup within the optic disc and the high density of vascular architecture traversing the optic cup boundary. One of the earliest reported methods was based on the discriminatory analysis of color intensity [8]. Later, in [9], pixels within the retinal image were classified based on pixel features generated from stereo color retinal images. Variational level set based on pixel intensity was used to globally optimize the obtained cup contour in [10]. In this study, we aim to find an optimized solution for optic cup detection. We presented and evaluated several segmentation and boundary detection methods. A fused approach based on multimodalities including level set segmentation, convex hull and ellipse fitting boundary is proposed. Convex hull [11] is the smallest region enclosing a specified group of points. The ellipse fitting algorithm is developed to better estimate the neuro-retinal optic cup boundary. The promising result will yield a large scale clinical trial in near future.

II. METHODOLOGY

ROI Determination

In order to extract the optic disc and cup, a region of interest around the optic disc must first be delineated, as the optic disc generally occupies less than 5% of the pixels in a typical retinal fundus image. While the disc and cup extraction can be performed on the entire image, localizing the ROI would help to reduce the computational cost as well as improve segmentation accuracy. To localize the boundary exactly the component labeling method is used. In the images, regions are labelled by using the neighbourhood connecting pixels. All the connected pixels with the same input value are assigned the same identification label. The component labelling method was shown in figure 4. The optic disc region is usually of a brighter pallor or higher color intensity than the surrounding retinal area. This characteristic is exploited through automatically selecting 0.5% of the pixels in the image with the highest intensity. Next, the retinal image is subdivided into 64 regions, and an approximate ROI centre is selected based on the region containing the highest number of pre-selected pixels. Following this, the ROI is defined as a rectangle around the ROI centre with dimensions of twice the typical optic disc diameter, and is used as the initial boundary for the optic disc segmentation, as shown in Figure 5.




Figure 3. Shows the simplified work flow of computer aided glaucoma diagnosis through CDR measurement.




Fig. 4. (a) Before labelling (b) After labelling.

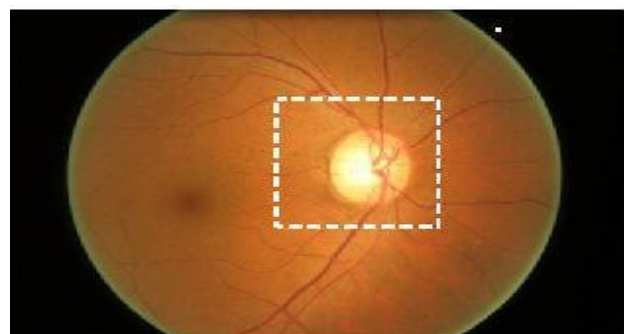


Figure 5. Retinal fundus image with the defined ROI in the outlined rectangle

Optic Disc Segmentation

To calculate the vertical cup to disc ratio, the optic cup and disc first have to be segmented from the retinal images. The optic disc extraction is straight forward and various approaches have been previously proposed for segmentation of the disc. In this paper, the disc boundary is detected using optimal color channel as determined by the color histogram analysis and edge analysis.

Optic Disc Smoothing

The disc boundary detected from the above step may not represent the actual shape of the disc since the boundary can be affected by a large number of blood vessels entering the disc. Therefore, ellipse fitting is performed to reshape the obtained disc boundary.

Optic Cup Segmentation

Compared to the extraction of the optic disc, cup segmentation provides an even greater challenge, as the cup-disc boundary is usually less pronounced than that of the disk region and is further compounded the increased visibility of blood vessels across the cup-disc boundary. To extract the cup from the optic disc, more robust image processing techniques are normally used to segment the cup.

Optic Disc Smoothing

After the cup boundary detection, ellipse fitting is again employed to eliminate some of the cup boundary's sudden changes in curvature. Ellipse fitting becomes especially useful when portions of the blood vessels in the neuro-retinal rim outside the cup are included with in the detected boundary. The CDR is consequentially obtained based on the height of detected cup and disc.

Ellipse Optimization for optic disc and cup

Ellipse fitting algorithm can be used to smooth the disc and cup boundary. Ellipse fitting is usually based on least square fitting algorithm which assumes that the best-fit curve of a given type is the curve that has the minimal sum of the deviations squared from a given data points (least square error). Direct Least Square Fitting Algorithm is chosen to fit the optic and cup over other popular ellipse fitting algorithms like Bookstein Algorithm and Taubin Algorithm. Instead of fitting general conics or being computationally expensive, this algorithm minimizes the algebraic distance subject to a constraint, and incorporates the ellipticity constraint into the normalization factor. It is ellipse-specific, thus the effect of noise (ocular blood vessel, hemorrhage, drusens, etc.) around the cup area can be minimized while forming the ellipse. It can also be easily solved naturally by a generalized Eigen system. In Fitting algorithm, a quadratic constraint is set on the parameters to avoid trivial and unwanted solutions. The goal is to search a vector parameter which contains the six coefficients of the standard form of a conic. An ellipse is a special case of a general conic which can be described by an implicit second order polynomial

$$F(x, y) = ax^2 + bxy + cy^2 + dx + ey + f = 0 \quad (1)$$

with an ellipse-specific constraint

$$b^2 - 4ac < 0 \quad (2)$$

Where a, b, c, d, e, f are coefficients of the ellipse and (x, y) are co-ordinates of points lying on it. The polynomial F(x, y) is called the algebraic distance of the point (x, y) to the given conic. By introducing vectors

$$\begin{aligned} \mathbf{a} &= [a, b, c, d, e, f]^T \\ \mathbf{x} &= [x^2, xy, y^2, x, y, 1] \end{aligned} \quad (3)$$

it can be rewritten to the vector form

$$F_a(\mathbf{x}) = \mathbf{x} \cdot \mathbf{a} = 0 \quad (4)$$

The fitting of a general conic to a set of points (x_i, y_i) , $i = 1 \dots N$ may be approached by minimizing the sum of squared algebraic distances of the points to the conic which is represented by the coefficient \mathbf{a} :

$$\min \sum_{i=1}^N F(\mathbf{x}_i, \mathbf{y}_i)^2 = \min \sum_{i=1}^N (F_a(\mathbf{x}_i))^2 \quad (5)$$

The problem (5) can be solved by the standard least squares approach, but the result of such fitting is a general conic and it need not to be an ellipse. To ensure an ellipse-specificity of the solution, the appropriate

constraint (2) have to be considered. Under a proper scaling, the inequality constraint in (2) can be changed into an equality constraint.

$$H_{convex}(X) = \{ \sum_{i=1}^k a_i x_i \mid x_i \in \mathcal{X}, a_i \geq 0, \sum_{i=1}^k a_i = 1, k = 1, 2, \dots \}$$

$$4ac - b^2 = 1 \quad (6)$$

and the ellipse-specific fitting problem can be reformulated as

$$\min \|\mathbf{D}\mathbf{a}\|^2 \quad \text{subject to} \quad \mathbf{a}^T \mathbf{C}\mathbf{a} = 1 \quad (7)$$

where the design matrix \mathbf{D} of the size $N \times 6$, represents the least squares minimization of (5) and the constraint matrix \mathbf{C} of the size 6×6 , express the constraint of (6). The minimization problem (7) is ready to be solved by a quadratically constrained least squares minimization. First, by applying the Lagrange multipliers we get the following conditions for optimal solution \mathbf{a} .

$$\begin{aligned} \mathbf{S}\mathbf{a} &= \lambda \mathbf{C}\mathbf{a} \\ \mathbf{a}^T \mathbf{C}\mathbf{a} &= 1 \end{aligned} \quad (8)$$

where \mathbf{S} is the scatter matrix of the size 6×6 ,

$$\mathbf{S} = \mathbf{D}^T \mathbf{D} \quad (9)$$

in which the operator \mathbf{S} denotes the sum

$$S_{ab} = \sum_{i=1}^N x_i^a y_i^b \quad (10)$$

Next, Eq. (8) is solved by using generalized Eigen vectors. There exist up to six real solutions, but by considering the minimization $\|\mathbf{D}\mathbf{a}\|^2$ subjected to the constraint (6) would yield only one solution, which corresponds by virtue of constraint, to an ellipse.

Convex hull based Ellipse Optimization

A convex hull of a set of points is the smallest convex polygon that contains every one of the points. It is defined by a subset of all the points in the original set.

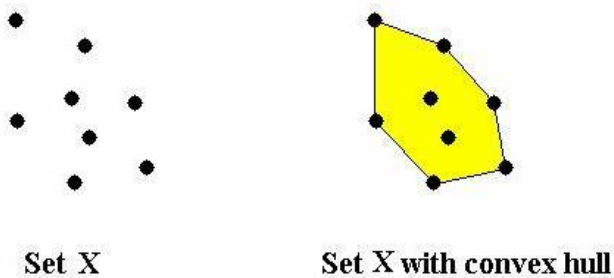


Figure 6. Example of a Convex Hull

The convex hull of X can also be described constructively as the set of convex combinations of finite subsets of points from X : that is, the set of points of the form, where n is an arbitrary natural number, the numbers t_j are non-negative and sum to $\mathbf{1}$, and the point's x_j are in X . It is simple to check that this set satisfies either of the two definitions above. So the convex hull $H_{convex}(X)$ of set X is:

$$H_{convex}(X) = \left\{ \sum_{i=1}^k a_i x_i \mid x_i \in X, a_i \geq 0, \sum_{i=1}^k a_i = 1, k = 1, 2, \dots \right\}$$

If X is a subset of an N -dimensional vector space, convex combinations of at most $N+1$ points are sufficient in the definition above. This is equivalent to saying that the

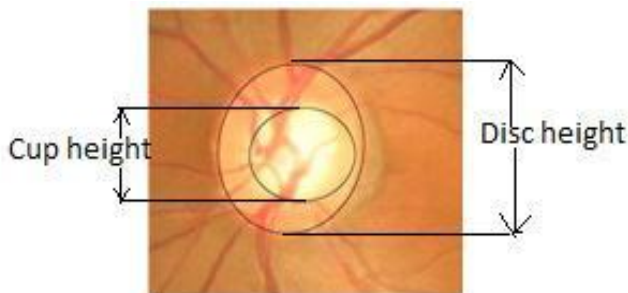


Figure 7. Ellipse fitted Optic Disc and Cup

Image Analysis

To evaluate the performance of proposed approach, the neuro-retinal images are obtained from Vasan eye Hospital. The Cup to Disc ratio for each neuro-retinal image was provided by the ophthalmologist using stereographic viewers and images were set as ground truth against which the performance of our proposed method was evaluated. The

performance of a CDR based glaucoma diagnosis system is largely dependent on how accurate a CDR is measured. The error ranges of our new fusion algorithm and Clinical CDR are compared in the experiment. It is found that the error range of fitting algorithm is smaller and is observed that the spread of CDR errors with respect to clinical values is less spaced out for the new algorithm (Table 1).

The risk of glaucoma is assessed based on CDR value; clinically a CDR greater than 0.65 indicates high glaucoma. From the plot (Figure 8), it is observed that, our new algorithm increases the chances of correct diagnosis. for segmentation of the disc. In this paper, the disc boundary is detected using optimal color channel as determined by the color histogram analysis and edge analysis.

TABLE 1: Comparison of clinical CDR value with our result.

Images	Clinical Cdr	Roi And Ellipse Fitting
		Method
G1	0.50	0.46
G2	0.65	0.64
G3	0.45	0.43
G4	0.60	0.64
G5	0.40	0.42
G6	0.45	0.45
G7	0.70	0.70
G8	0.30	0.32

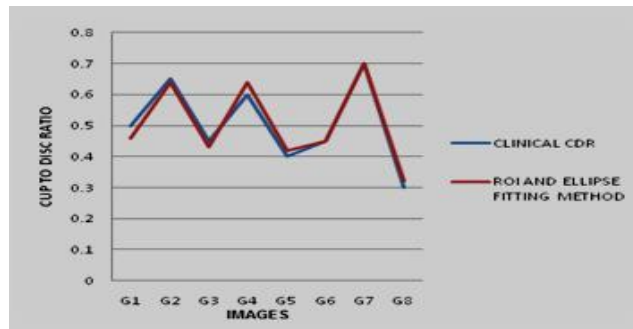



Figure 8: Comparison of clinical CDR and CDR from Ellipse fitting.

III. CONCLUSION

This paper presented and evaluated for a more accurate estimation of neuro-retinal optic cup based on multimodalities including labeling method, convex hull and ellipse fitting methods. To determine the performance of our approach, few retinal images were processed and their CDR was calculated. Comparing with the clinical values, the new approach achieves a better CDR value, which results to more accurate Glaucoma Diagnosis. The good performance of the new approach leads to a large scale clinical evaluation and will be able to report large clinical findings in the future.

REFERENCES

1. J. Dammas and F. Dannheim, "Sensitivity And Specificity Of Optic Disc Parameters In Chronic Glaucoma", Invest ophth VisSci, vol.34.pp.2246-2250, June.1993.



2. Thylefors. B and Negrel, "The Global Impact Of Glaucoma", Bull World Health Organ, vol.72, no.3,pp 32-36, 1994.
3. Quigley. H. A and A. T. Broman, "The Number Of People With Glaucoma Worldwide In 2010 And 2020" Br. J. Ophthalmol, vol.90, no.3, p.262-7,2006.
4. J. Xu, O. Chutatape, E. Sung, C. Zheng, P. C. T. Kuan. "Optic Disk Feature Extraction Via Modified Deformable Model Technique For Glaucoma Analysis" Pattern Recognition , vol.40, pp. 2063-2076, 2006.
5. H. Li, O. Chutatape. "A model-based approach for automated feature extraction in fundus images". In Proc. Of the 9th IEEE International Conference on Computer Vision, 2003.
6. N. Inoue, K. Yanashima, K. Magatani, and T.A. K. T. Kurihara, "Development of a simple diagnostic method for the glaucoma using ocular Fundus pictures," 27th Annual International Conference of the Engineering in Medicine and Biology Society, 2005.
7. M. D. Abramoff, W. L. M. Alward, E. C. Greenlee, L. Shuba, C. Y. Kim, J. H. Fingert, and Y. H. Kwon, "Automated Segmentation of the Optic Disc from Stereo Color Photographs Using Physiologically Plausible Features," Investigative Ophthalmology and Visual Science, vol. 48, pp. 1665, 2007.
8. J. Liu, D.W.K. Wong, J.H. Lim, H. Li, N.M. Tan, Z.Zhang, T. Y Wong, R. Lavanya, "ARGALI: An Automatic Cup-To-Disc Ratio Measurement System For Glaucoma Analysis Using Level-Set Image Processing", International Conference on Biomedical Engineering (ICBME2008), 2008.
9. Brown, K. Q. "Voronoi Diagrams From Convex Hulls". Information Processing Letters, vol. 9, no.5, pp. 223-228 ,1979.
10. Rafael C. Gonzalez, Richard E. Woods, "Digital Image Processing Using MATLAB", Second Edition, Pearson Education Asia Publications.
11. R.S.Khandpur, "Handbook of Biomedical Instrumentation", Second Edition, Tata McGraw- Hill Publications